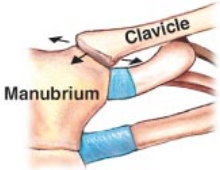
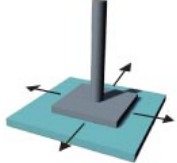

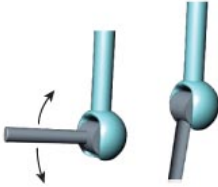
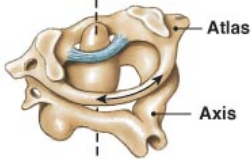
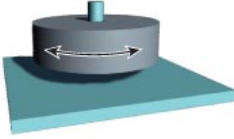

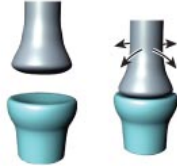
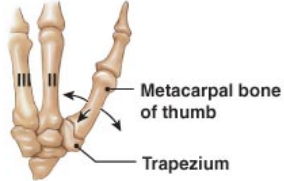
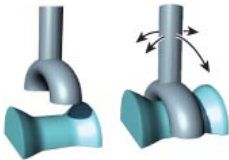
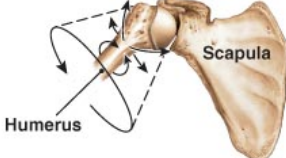
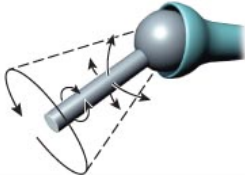


# Synovial Joint Types

The anatomical types of synovial joints, with joint models and examples

Types of Synovial Joints	Models of Joint Motion	Examples
<p><b>Gliding joint</b></p> 		<ul style="list-style-type: none"> <li>• Acromioclavicular and sternoclavicular joints</li> <li>• Intercarpal and intertarsal joints</li> <li>• Vertebrocostal joints</li> <li>• Sacro-iliac joints</li> </ul>
<p><b>Hinge joint</b></p> 		<ul style="list-style-type: none"> <li>• Elbow joints</li> <li>• Knee joints</li> <li>• Ankle joints</li> <li>• Interphalangeal joints</li> </ul>
<p><b>Pivot joint</b></p> 		<ul style="list-style-type: none"> <li>• Atlas/axis</li> <li>• Proximal radio-ulnar joints</li> </ul>
<p><b>Ellipsoid joint</b></p> 		<ul style="list-style-type: none"> <li>• Radiocarpal joints</li> <li>• Metacarpophalangeal joints 2-5</li> <li>• Metatarsophalangeal joints</li> </ul>
<p><b>Saddle joint</b></p> 		<ul style="list-style-type: none"> <li>• First carpometacarpal joints</li> </ul>
<p><b>Ball-and-socket joint</b></p> 		<ul style="list-style-type: none"> <li>• Shoulder joints</li> <li>• Hip joints</li> </ul>